

Case report

Papular eosinophilic/mastocytic dermatitis (feline urticaria pigmentosa) in Devon Rex cats: A distinct disease entity or a histopathological reaction pattern?

CHIARA NOLI*†, SILVIA COLOMBO‡, FRANCESCA ABRAMO§
and FABIA SCARAMPELLA*

*Studio Dermatologico Veterinario, Via Sismondi 62, 20133 Milan, Italy

†BiEsseA Laboratorio di Analisi Veterinarie, Via Amedeo d'Aosta 7, 20129 Milan, Italy

‡Department of Veterinary Clinical Studies, Royal (Dick) School of Veterinary Studies, Hospital for Small Animals, Easter Bush Veterinary Centre, Roslin, Midlothian EH25 9RG, UK

§Department of Animal Pathology, University of Pisa, Via delle Piagge 2, 56124 Pisa, Italy

(Received 25 November 2002; accepted 9 September 2003)

Abstract A maculopapular eruption with clinical and histological features similar to those previously described in Sphinx cats under the name of urticaria pigmentosa is reported in five unrelated Devon Rex cats. Physical examination revealed erythematous, occasionally crusted papules, with a bilaterally symmetrical linear distribution on the latero-ventral trunk in two cases and a diffuse distribution on the ventral thorax in the other three cats. One cat also had a greasy seborrhoea on the head and dorsum. Pruritus and pigmented macules were present only in cats affected by secondary bacterial infection. Histological examination of papules in all cats and of the lesional skin of the cat affected by greasy seborrhoea revealed the presence of a perivascular to diffuse mastocytic and eosinophilic infiltrate in the dermis. The mean numbers of nondegranulated and degranulated mast cells per mm² were 303.2 and 451.6, respectively. The condition waxed and waned in all cats, and exacerbations were controlled with prednisolone or essential fatty acids.

Keywords: cat, mast cell, skin, urticaria pigmentosa.

INTRODUCTION

In humans, urticaria pigmentosa is a generalized cutaneous form of mast cell proliferation (mastocytosis) that causes pruritus, whealing and red–brown macules or papules particularly over the trunk.^{1–3} Half of the cases occur in infancy and its cause is unknown. Systemic malignant involvement is rare. Histologically, numerous mast cells are present in the dermis, usually associated with eosinophils.² Mast cells are spherical in shape and have abundant, intensely eosinophilic, granular cytoplasm and a small hyperchromatic nucleus.⁴ Treatment of human urticaria pigmentosa is symptomatic, based on avoidance of factors triggering acute mediator release, antihistamines, photochemotherapy, topical steroids and mast cell stabilizing agents.^{2,3}

A skin eruption clinically and histopathologically similar to urticaria pigmentosa in humans has been observed in dogs and young Himalayan cats,⁵ and has been recently described in three related Sphinx cats.⁶ The main clinical feature in the latter report was a pruritic, maculopapular, bilaterally symmetrical, partially

pigmented and crusted eruption on the trunk, limbs, neck and head. On histopathological examination, a perivascular to diffuse dermal and subcutaneous infiltrate of well-differentiated mast cells was observed. Therapy with hydroxyzine and prednisone was effective in one case.

We report here five further cases of what we believe to be the same or a very similar condition in unrelated Devon Rex cats.

CASES

Five Devon Rex cats (Table 1) were presented with a history of variably pruritic skin disease ranging from 3 weeks to 10 months. All cats were regularly vaccinated, received flea control products, were fed a commercial canned/dry food and lived indoors (two cats) and indoors/outdoors (three cats). Only one cat (Case 1) had received treatment prior to referral (prednisolone 0.5 mg kg⁻¹ once daily for 10 days), which resulted in remission of the clinical signs, but the skin disease had relapsed after discontinuation of therapy. On physical examination, all cats were healthy with abnormalities restricted to the skin.

Correspondence: C. Noli, Strada Madonna 58, 12016 Peveragno (CN), Italy. E-mail: pitnoli@iol.it

Table 1. Signalment and clinical data of five Devon Rex cats with papular mastocytic/eosinophilic dermatitis

Case	Age	Sex	Duration	Lesions and distribution	Pruritus	Pyoderma
1	3 y	MN	10 m	Erythematous, hyperpigmented papules, abdomen, groin, neck	Yes	Yes
2	10 m	F	1 m	Erythematous, hyperpigmented papules, linear distribution Ventral thorax, abdomen	Yes	Yes
3	4 y	F	3	Papular eruption Linear distribution Thorax, abdomen	No	No
4	4 y	M	1 m	Seborrhoeic, erosive dermatitis, hypotrichosis, dorsum, head Papular eruption Ventral neck, thorax	No	No
5	1 y	M	3 w	Erythematous papular eruption Ventral thorax, flanks	Yes	Yes

F: female; M: male; N: neutered; w: weeks; m: months; y: years.

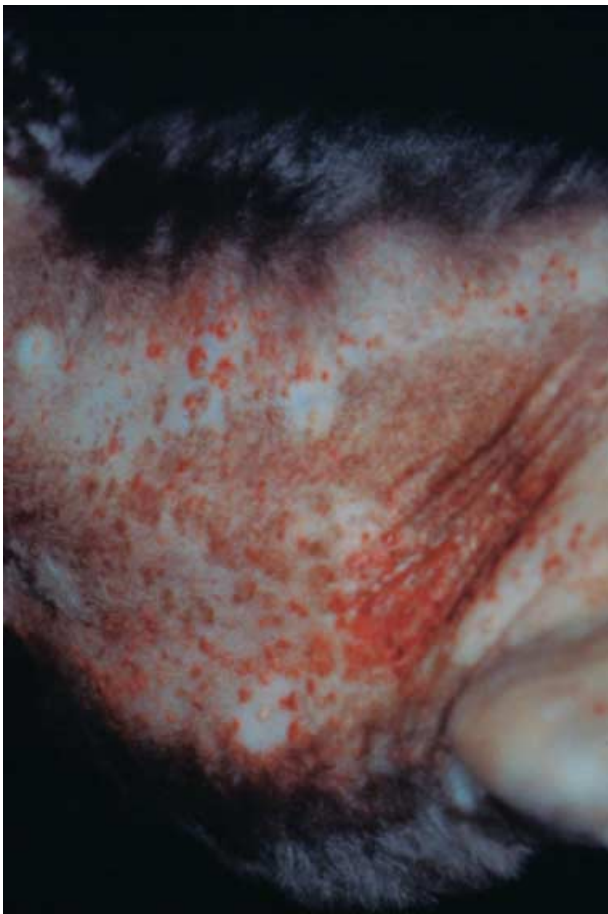

Figure 1. Case 1: Multiple erythematous, crusted coalescing papules on the abdomen and groin.

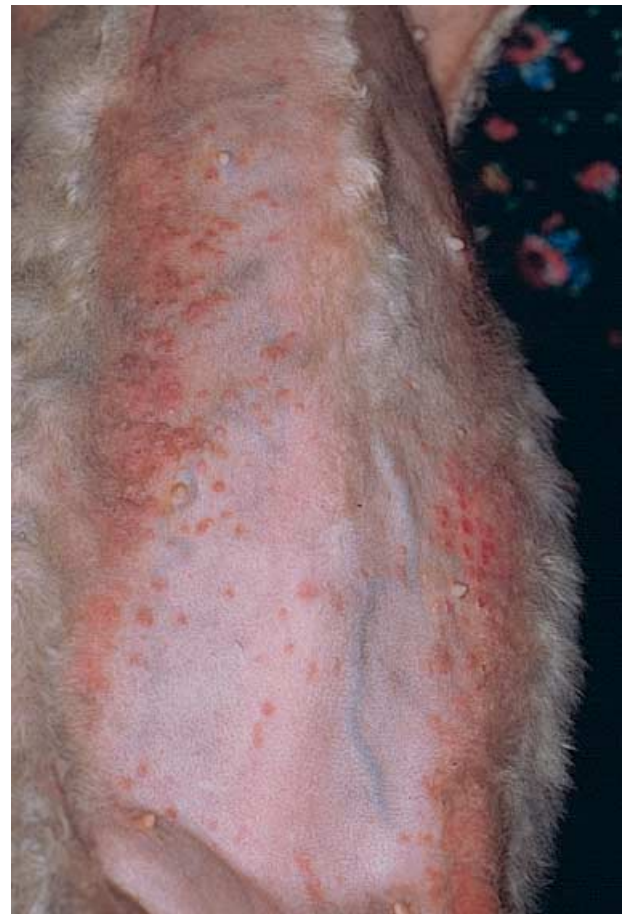

Figure 2. Case 3: Bilaterally symmetrical, linear papular eruption on the thorax and abdomen.

Dermatological examination revealed similar lesions in all cats. In Case 1, there were multiple, erythematous, coalescing, crusted and hyperpigmented papules on the abdomen, groin and ventral neck (Fig. 1) and an erythematous, exudative, raised plaque on the abdomen, which was clinically suggestive of an eosinophilic plaque. Case 2 showed multiple, erythematous, exudative or crusted and partly hyperpigmented coalescing papules arranged in a bilateral, linear distribution on the ventral lateral thorax and abdomen. In Case 3, a bilaterally symmetrical linear papular eruption on the thorax and abdomen and a greasy, seborrhoeic, erosive

dermatitis with hypotrichosis on the dorsum and head were observed (Figs 2–4). Case 4 presented with a diffuse papular eruption on the ventral neck and thorax (Fig. 5). In Case 5 there was a diffuse, erythematous papular eruption on the ventral thorax and flanks (Fig. 6), where small hyperpigmented macules were also observed (Table 1).

Differential diagnoses included urticaria pigmentosa-like dermatitis, atopic dermatitis, food hypersensitivity, flea bite hypersensitivity, dermatophytosis, mast cell tumour and superficial bacterial folliculitis. In addition, *Malassezia* dermatitis, feline paraneoplastic

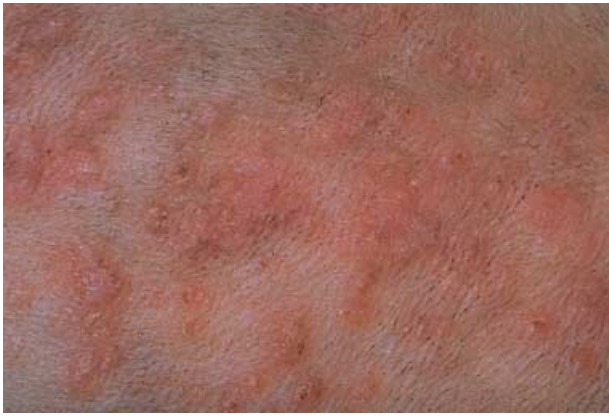

Figure 3. Same cat as Fig. 2: the skin lesions are represented by small erythematous papules, occasionally covered by tiny crusts.

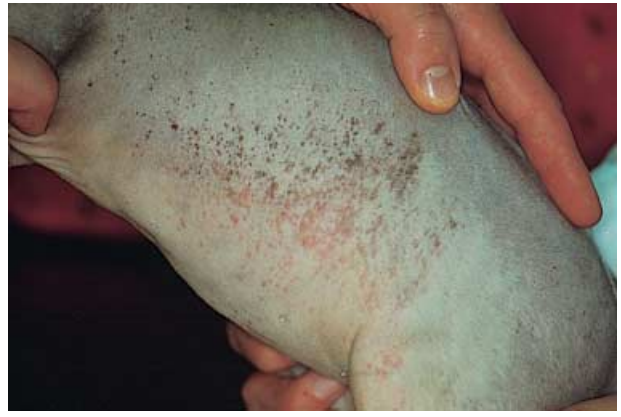

Figure 6. Case 5. Erythematous papules and hyperpigmented macules on the flank.

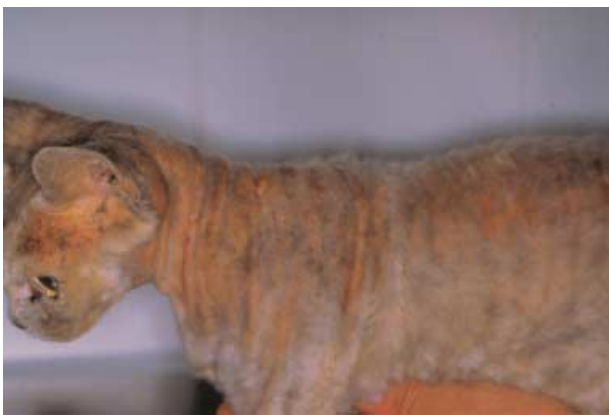

Figure 4. Same cat as Figs 2 and 3: Greasy, seborrhoeic, erosive dermatitis with hypotrichosis on the dorsum and head.

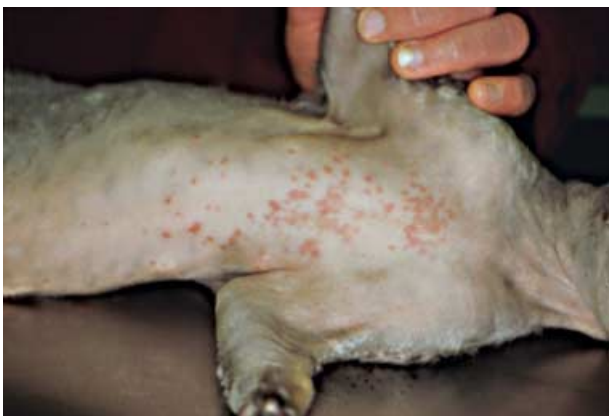

Figure 5. Case 4: Erythematous papules on the thorax.

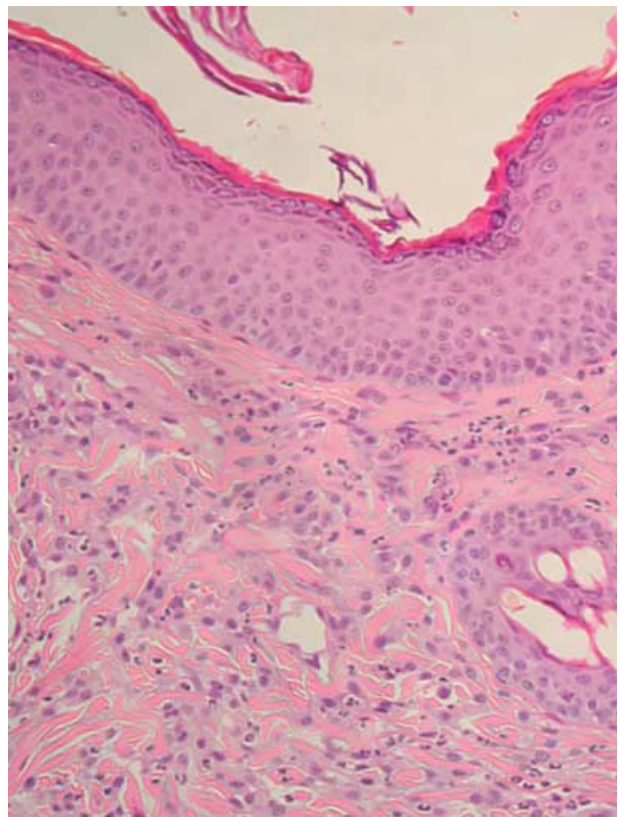


Figure 7. Case 2: Histological section showing an interstitial to diffuse dermal infiltration of mast cells and eosinophils (H&E, $\times 750$).

syndromes, feline mural folliculitis and sebaceous adenitis were considered as differential diagnoses for the seborrhoeic dermatitis observed in Case 3.

Multiple skin scrapings, coat brushings and fungal cultures were performed in all cats and were negative. Cytological examination of material obtained from underneath crusts was performed in Cases 1, 2 and 5 and showed large numbers of degenerate neutrophils with intracellular and extracellular cocci, suggestive of

a secondary superficial pyoderma. Moderate numbers of eosinophils were also present in Case 1. Cytological examination of an impression smear from the exudative plaque in Case 1 revealed eosinophilic inflammation, consistent with an eosinophilic plaque.

In Cases 1 and 2, preliminary treatment was prescribed, comprising methyl-prednisolone acetate (Depo-medrol®, Pharmacia & Upjohn) injections at a dose of 20 mg per cat given subcutaneously two weeks apart in Case 1 and cephalexin (Rilexine®, Virbac) at 25 mg kg⁻¹ twice daily for 3 weeks in both cases. The eosinophilic plaque in Case 1 completely resolved, while the other lesions either did not resolve or relapsed after discontinuation of treatment in both cases.

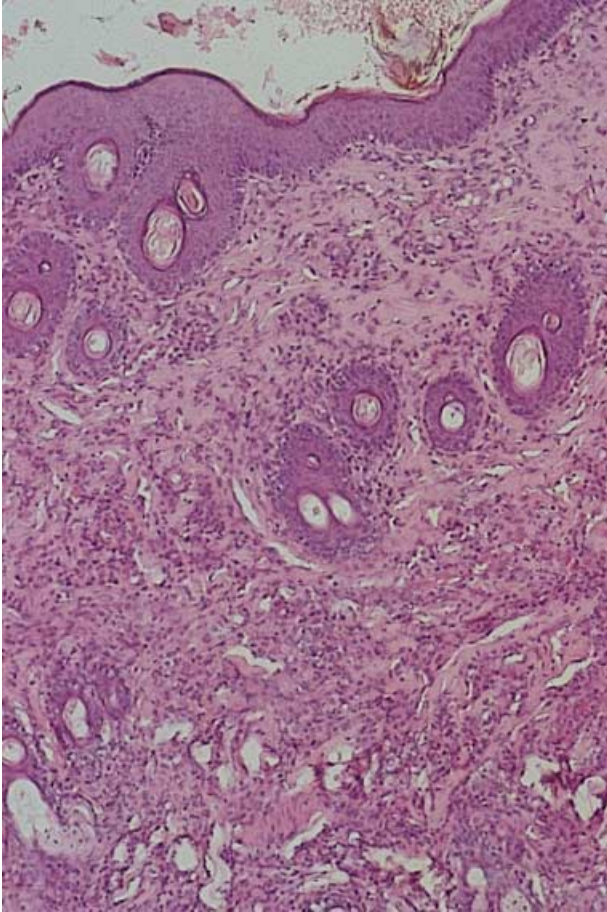


Figure 8. Case 3: Histological section showing a perivascular to interstitial infiltrate of mast cells and eosinophils in the superficial to deep dermis (H&E, $\times 100$).

Biopsies were obtained from all five cats. Specimens were fixed in 10% buffered formalin and stained with haematoxylin and eosin (H&E), periodic acid Schiff (PAS) and toluidine blue (TB). Histopathological examination revealed irregular (Case 1) or regular (Case 2) epidermal hyperplasia, with spongiosis, focal eosinophilic exocytosis (Cases 4 and 5) and a few sub-corneal eosinophilic pustules (Cases 1, 4 and 5). In Case 1, there were also focal aggregates of melanin pigment within the keratinocytes in the suprabasal layers and stratum corneum. In these areas, pigmentary incontinence was present. In all cases, the dermis was infiltrated by well-differentiated mast cells and eosinophils, with variable patterns of severity and distribution. These ranged from mild to severe and from superficial, interstitial and diffuse to deep perivascular infiltration. Mast cells were uniformly distributed and contained variable amounts of TB positive granules (Figs 7–8). Case 2 also showed focal interstitial to diffuse neutrophilic inflammation. In Case 3, biopsies from the seborrhoeic areas on the dorsum revealed a moderate superficial interstitial dermatitis comprising well-differentiated, granule-rich mast cells and eosinophils. Focal aggregates of melanocytes and melanin pigment were detected in the overlying epidermis, and melanophages were present in the dermis.

Morphometric analysis of mast cell numbers was performed using a Quantimet 500 analyser system (Leica Microsystems, S.p.A., Milan, Italy) on TB-stained sections. Microscopic fields were captured at high power ($\times 40$) and the number of nucleated mast cells for each dermal site calculated. Mast cells in close proximity to follicular units were not included. Data were expressed as number of counted cells per mm^2 . The mean number of mast cells with many intracytoplasmic granules was 303.2 ($\text{SD} = 138.7$) cells/ mm^2 , whereas the mean number of degranulated mast cells, containing a few intracytoplasmic granules, was 451.6 ($\text{SD} = 216.1$). The mean numbers of nondegranulated and degranulated mast cells per high power field ($\times 400$) were 89 and 132, respectively.

The results of the histopathological examinations were suggestive of urticaria pigmentosa-like dermatitis, with hypersensitivity disorders as possible differential diagnoses. An elimination diet to investigate the possibility of food hypersensitivity was suggested to the owners of Cases 2, 3, 4 and 5. The diet was carried out in Case 4 only (horse meat for 6 weeks), but no improvement was observed.

Various treatments were prescribed in the five cases (Table 2). The condition was successfully controlled with prednisolone (Deltacortene®, Lepetit) at anti-inflammatory doses (2 mg kg^{-1} orally once daily, followed by 1 mg kg^{-1} every other day) in Cases 1 and 3, and with blackcurrant seed oil (Ribespet®, NBF Lanes) as a source of biotransformed essential fatty acids administered at twice the manufacturer's recommended dose (0.05 mL kg^{-1}) in Cases 2 and 4. Case 5 responded to a combination of cyproheptadine (Periactin®, Neo-farmamed) (1 mg kg^{-1} orally twice daily) and amoxicillin/clavulanic acid (Synulox®, Pfizer) (20 mg kg^{-1} orally twice daily). In all cases, the condition relapsed when the treatments were discontinued, and went into remission again with they were resumed (Table 2). In Case 2, mild relapses of the disease, which seemed to spontaneously wax and wane, were seen despite continuation of essential fatty acid administration.

DISCUSSION

Mastocytosis consists of a group of rare disorders characterized by a pathological increase in mast cells in tissues including skin, bone marrow, liver, spleen and lymph nodes.^{1,3} The most common clinical sign of mastocytosis is the presence of typical skin lesions of urticaria pigmentosa.³ Recently, it has been shown that adult-onset systemic mastocytosis is a clonal disorder often exhibiting mutations of *c-kit*, a proto-oncogene encoding the tyrosine kinase receptor for stem cell factor, whereas most cases of childhood-onset and familial mastocytosis seem to lack these mutations.⁷ Despite the presence of *c-kit* mutations, patients with skin disease generally carry a good prognosis, even if other organs are involved. Mutations of *c-kit* do not explain the initial cause of mastocytosis, and their prognostic

Table 2. Treatments and outcome of five Devon Rex cats with papular mastocytic/eosinophilic dermatitis

Case	Treatment	Response and outcome
1	EFA Prednisolone (1 month)	No improvement Remission Relapses controlled with prednisolone
2	EFA	Remission, treatment continued Minor waxing and waning relapses
3	Prednisolone (1 month)	Remission Relapses controlled with prednisolone
4	Oxatomide, prednisolone (1 month) EFA	Partial improvement Remission Relapses controlled with EFA
5	Amoxicillin/clavulanic acid (3 weeks) and EFA Amoxicillin/clavulanic acid and cyproheptadine (3 weeks)	Remission and relapse while on EFA only Remission Relapses controlled with amoxicillin/clavulanic acid and cyproheptadine

Treatments: EFA: Blackcurrant seed oil (Ribespet®, NBF Lanes) 0.05 mL kg⁻¹ orally once daily; Prednisolone: (Deltacortene®, Lepetit) 2 mg kg⁻¹ orally once daily, followed by 1 mg kg⁻¹ every other day; Oxatomide: (Tinset®, Formenti) 15 mg kg⁻¹ orally twice daily; Amoxicillin/clavulanic acid: (Synulox®, Pfizer) 20 mg kg⁻¹ orally twice daily; Cyproheptadine: (Periactin®, Neofarmamed) 1 mg kg⁻¹ orally twice daily.

significance is not yet known, nor is the pathogenesis of the disease in persons without the mutations.⁷ Furthermore, these recent data have not as yet resulted in a more effective therapy of the disorder, so that prevention of exposure to mast cell secretory stimuli and symptomatic treatment remain the basis of current patient management.^{4,7}

This is the first time that the disease named 'feline urticaria pigmentosa' or 'urticaria pigmentosa-like dermatitis' has been described in detail in a breed other than the Sphinx cat. A genetic predisposition was suggested in the Sphinx breed,⁶ as the three cats in the case series shared the same grandsire. Our cases occurred in unrelated cats, and in a different breed. However, the fact that the five cats in our report were all Devon Rex could support a genetic predisposition. Cats of this breed probably share numerous genes, as Devon Rex cats were created only recently by inbreeding one single ancestor individual. It is worth mentioning that, even if phenotypically similar, Sphinx and Devon Rex cats are genotypically unrelated. It is thus interesting that this disease has been recognized until today mainly in hypotrichotic or naked animals. It may be that hypotrichotic or naked breeds are predisposed, or that this skin condition, when occurring in an asymptomatic nonpruritic fashion, could go unrecognized in normally haired animals. However, as some of the affected cats show pruritus, the disease should be easily recognized also in haired animals, because of its striking clinical appearance.

Clinically, the condition described in the report by Vitale and co-workers⁶ is similar to that seen in our animals, with the exception that some of the cats in the present report (Cases 3 and 4) were not pruritic and did not have hyperpigmented macules. In our series, pruritus and hyperpigmented macules were observed only in cats whose lesions were secondarily infected (Cases 1, 2 and 5). In the report by Vitale *et al.*, cytological examination of the lesions was not reported, and details about possible bacterial complications were not presented. It is possible therefore that this condition may

not be pruritic *per se*, and hyperpigmentation could have been induced by secondary bacterial infection.

On histopathological examination, mast cells were always well differentiated and easily recognized in H&E-stained sections, owing to their typical morphology. Despite their high number, the lack of cytological atypia allowed us to exclude a neoplastic process. In normal cats, the mean number of mast cells per high power field (×400) was 12.5 (range: 0–60).⁸ In our cases, the mean numbers/mm² of nondegranulated and degranulated mast cells were 303.2 and 451.6, respectively. This equates to 89 nondegranulated and 132 degranulated mast cells per high power field (×400). These values were therefore much higher than those observed in normal cats. This finding was comparable with that observed in lesional skin of animals with eosinophilic plaque and eosinophilic granuloma.⁸ In none of the cases were areas of flame figures (amorphous eosinophilic material, also erroneously called 'collagenolysis') detected, however, the absence of this feature does not allow us to completely exclude lesions of the eosinophilic granuloma complex, as not all eosinophilic plaques and granulomas are characterized by the presence of flame figures.⁹ In fact, histopathology alone could not clearly differentiate between 'urticaria pigmentosa-like dermatitis' and other feline eosinophilic conditions, such as the eosinophilic granuloma, the eosinophilic plaque, atopic dermatitis, food hypersensitivity and flea-bite hypersensitivity. Even if the clinical signs are very suggestive, because of the histological pattern of nonspecific eosinophilic dermatitis, one cannot exclude the possibility that what we call 'feline urticaria pigmentosa' or 'urticaria pigmentosa-like dermatitis' is just one of many feline reaction patterns of hypersensitivity disorders, such as the eosinophilic granuloma or the eosinophilic plaque. The seborrhoeic condition seen on the back of the third cat, also featuring a diffuse mastocytic infiltrate on histopathological examination, was not described in the report by Vitale *et al.*⁶ or in any other previous reports, and it is unknown if it is part of the same condition or not.

A minor difference between the cases described by Vitale *et al.*⁶ and this case series is represented by the amount of eosinophils observed in the histological sections. In the report by Vitale, a small number of eosinophils were observed in two cats and a minimal eosinophilic infiltrate in the third, whereas in our report eosinophils were present in high numbers in all sections. This difference may represent a variant of the same disease, this may be due to the different breed or it may be that the disease described by Vitale *et al.* is not the same as the one observed in our cats. Eosinophils are usually present in sections from human urticaria pigmentosa.⁴

Owing to the presence of a dense infiltrate of mast cells and eosinophils, the possibility of this condition being a sign of an underlying allergic disease was considered. The finding of consistent eosinophilia in the cats described by Vitale *et al.*⁶ supports this hypothesis. The fact that in some cats the lesions were easily controlled with glucocorticoids and in others with essential fatty acids or antihistamines supports the hypothesis that this disease may be an allergic reaction pattern, even if in Case 4 food allergy was pursued with no success and intradermal skin testing was not carried out in any cat. Thus it is important to stress that an underlying hypersensitivity could not be ruled out in these cases, and we suggest that animals presenting with similar clinical and histological pattern should always have a diagnostic work up for underlying allergies.

It is not known if the conditions described by Vitale *et al.*⁶ and those in our report are the same as the human disease. Urticaria pigmentosa in humans is a form of mastocytosis^{1-4,7} which usually occurs early in life (less than 6 months of age) and spontaneously resolves at puberty in 50% of the children, although in a minority of the cases it progresses to a systemic disease. The feline disease described in our report and that reported by Vitale occur in young adult cats and have similar clinical and histological features, with a good clinical prognosis. However, the number of cats with this condition observed to date is too low to exclude a systemic progression of this disease. The authors suggest that, until we know for sure whether this is a distinct disease or the same as the human condition, it

should not be called 'feline urticaria pigmentosa' or 'urticaria pigmentosa-like dermatitis'. The term 'papular eosinophilic/mastocytic dermatitis' would appear to be more appropriate.

ACKNOWLEDGEMENTS

The authors would like to thank the Veterinary Clinic of Drs Canepa and Neri, Novara, the Veterinary Clinic of Drs Canepa and Portigliotti, Novara, the Veterinary Clinic S. Siro, Milan, and the Veterinary Clinic Gran Sasso, Milan, for referring the cats to the authors. We would also like to thank Dr Antonella Vercelli for the histological diagnosis of Case 2.

REFERENCES

1. Metcalfe DD. The mastocytosis syndrome. In: Freedberg, IM, Eisen AZ, Wolff K *et al.*, eds. *Dermatology in General Medicine*, 5th edn. New York: McGraw-Hill, 1999: 1902-8.
2. Du Vivier A. *Atlas of Clinical Dermatology*, 2nd edn. London: Goven Medical Publishing, 1993; 4-5.
3. Escribano L, Akin C, Castells M *et al.* Mastocytosis: current concepts in diagnosis and treatment. *Annals of Hematology* 2002; 81: 677-90.
4. McKee Ph H. *Essential Skin Pathology*. London: Mosby Year Book, 1999: 15.
5. Muller GH, Kirk RW, Scott DW. *Small Animal Dermatology*, 6th edn. Philadelphia: W.B. Saunders, 2001: 997-9.
6. Vitale CB, Ihrke, PJ, Olivry T *et al.* Feline urticaria pigmentosa in three related Sphinx cats. *Veterinary Dermatology* 1996; 7: 227-33.
7. Hartmann K, Henz BM. Mastocytosis: recent advances in defining the disease. *British Journal of Dermatology* 2001; 144: 482-95.
8. Foster AP. A study of the number and distribution of cutaneous mast cells in cats with disease not affecting the skin. *Veterinary Dermatology* 1994; 5: 17-20.
9. Scarpella F, Abramo F, Noli C. Clinical and histological evaluation of an analogue of palmitoylethanolamide, PLR 120 (co-micronized Palmidrol INN) in cats with eosinophilic granuloma and eosinophilic plaque: a pilot study. *Veterinary Dermatology* 2001; 12: 29-39.

Résumé Cet article décrit une éruption maculopapuleuse chez cinq chats Devon Rex, qui ressemble sur le plan clinique et histopathologique aux cas précédemment rapportés chez les Sphinx sous le terme d'urticaire pigmentaire. L'examen clinique a montré des papules érythémateuses, parfois croûteuses, localisées de façon linéaire et symétrique sur la surface latéro-ventrale du tronc dans deux cas, et dans trois cas de façon diffuse sur la surface ventrale du thorax. Un chat présentait également une séborrhée grasse sur la tête et le dos. La présence de prurit et de macules pigmentées n'a été observée que chez les animaux souffrant d'une infection bactérienne secondaire. L'examen histologique des papules et de la séborrhée grasse a montré la présence d'un infiltrat dermique périvasculaire à diffus, constitué de mastocytes et d'éosinophiles. Les nombres moyens de mastocytes non dégranulés et dégranulés étaient respectivement de 303.2/mm² et 451.6/mm². La dermatose a évolué en dents de scie dans tous les cas, les poussées étant contrôlées avec l'utilisation de prednisolone ou d'acides gras essentiels.

Resumen Se describe en cinco gatos Devon rex no relacionados una erupción maculopapular con características clínicas e histológicas similares a las descritas previamente en gatos Sphinx bajo el nombre de urticaria pigmentosa. El examen físico mostró pápulas eritematosas, ocasionalmente pápulas costrosas, con una distribución

simétrica bilateral lineal en el tronco latero-ventral en dos casos, y una distribución difusa en el tórax ventral en los otros tres casos. Un gato mostraba también una seborrea oleosa en la cabeza y el dorso. El prurito y las máculas pigmentadas se encontraban presentes sólo en gatos afectados por una infección bacteriana secundaria. El examen histológico de pápulas en todos los gatos y en la piel lesionada del gato afectado por seborrea oleosa reveló la presencia de un infiltrado dérmico mastocítico y eosinofílico, perivascular a difuso. El número medio de mastocitos no-degranulados y degranulados /mm² fue de 303.2 y 451.6, respectivamente. El cuadro fue recidivante en todos los gatos, y el agravamiento fue controlado con prednisona o ácidos grasos esenciales.

Zusammenfassung Bei fünf nicht miteinander verwandten Devon Rex Katzen wird über einen maculopapulären Hautausschlag berichtet, der mit klinischen und histologischen Eigenschaften einhergeht, die denen ähnlich sind, die vorher bei Sphinx Katzen unter dem Namen Urticaria pigmentosa beschrieben wurden. Die klinische Untersuchung zeigte bei zwei Fällen erythematöse, gelegentlich verkrustete Papeln in bilateral symmetrischer, linearer Verteilung im Bereich des latero-ventralen Stammes und bei den anderen drei Katzen eine diffuse Verteilung im Bereich des ventralen Thoraxes. Eine Katze hatte zusätzlich ölige Seborrhoe im Bereich des Kopfes und des Rückens. Juckreiz und pigmentierte Maculae waren nur bei den Katzen vorhanden, die von einer sekundären bakteriellen Infektion betroffen waren. Die histologische Untersuchung von Papeln bei allen Katzen und läsionaler Haut bei der Katze mit ölgiger Seborrhoe zeigte ein perivaskulär bis diffuses Infiltrat mit Mastzellen und Eosinophilen in der Dermis. Die durchschnittliche Anzahl von nicht-degranulierten und degranulierten Mastzellen pro mm² war 303,2, bzw. 451,6. Bei allen Katzen kam und ging die Erkrankung und Verschlechterungen konnten mit Prednisolon und essentiellen Fettsäuren beherrscht werden.